




Gelflex 

Australian contact lenses

PROFESSIONAL FITTING GUIDE

ORTHOKERATOLOGY

 (03) 9792 3127 · 1800 335 559

 (03) 9793 1635

 orders@gelflex.com

 www.gelflex.com

ORTHOKERATOLOGY

INTRODUCTION

Gelflex Ortho-K has been designed and developed over many years using data collected from thousands of patients.

Ortho-k not only provides temporary correction of myopia but more and more research is espousing the benefits of ortho-k lenses as a myopia management strategy.

This fitting guide is designed to help you get started. With the support from our highly experienced Technical Service Team, now is the time to start fitting ortho-k lenses in your practice. Ortho-k is a unique service that creates patient loyalty, will help to grow the profitability of your practice, and most importantly provide a wonderful refractive option for your patients, especially those with active lifestyles.

Suggested reading:


Free download, <https://contemporaryorthokeratology.com/>

Author - Michael Lipson OD FAAO FSLC

ESTABLISHING EXPECTATIONS

Patient and practitioner expectations: These include vision, comfort, wearing time, cost and follow-up care. Patient expectations must be realistic and match what the practitioners can realistically deliver. If the patient expects more than what can be delivered, their satisfaction will not be realised even if the outcome is ideal.

Practitioners must spell out their expectations to the patient/parent regarding all aspects of the ortho-k process. This must include realistic and detailed explanations of the benefits, risks and limitations of Ortho-k. Guarantees should never be made as to the exact outcome or rate of changes during Ortho-k. Statistics can be demonstrated from your practice as well as results reported in the literature, but caution is advised not to make unsubstantiated claims. Statements about 6/6 are best deleted and reference to the best possible functional vision should be made. Although outcomes with Ortho-k are usually quite predictable, remind patients and parents that each patient may respond differently.



FITTING GUIDE & LENS CARE

STEP 1

PATIENT SELECTION

We recommend that practitioners who are new to fitting Gelflex Ortho-k start with patients with myopia in the range of -1.00D to -3.00D and no more than 1.00D of “with the rule astigmatism”.

With more experience, you can start to treat more complex cases. Your ideal patient will:

1. Have realistic expectations of visual outcomes
2. Be committed to and compliant with your prescribed follow-up schedule
3. Follow lens cleaning and handling instructions (or a responsible adult can supervise)

We do NOT recommend Ortho-k for patients with the following conditions.

1. Acute and subacute inflammation or infection of the anterior segment of the eye
2. Any eye disease, injury, or abnormality that affects the cornea, conjunctiva, or eyelids.
3. Severe insufficiency of tears (Dry eyes)
4. Corneal Hypoesthesia (reduced corneal sensitivity)
5. Any systemic disease that may affect the eye or exacerbated by wearing contact lenses.
6. Allergy to any ingredient in a solution which is to be used for contact lens care.
7. Any active corneal infection (bacterial, fungal, or viral)
8. History of corneal surgery.
8. Patients who sleep less than 6 hours a night may not achieve optimal results.

STEP 2

INITIAL EXAMINATION

At the initial examination we recommend adhering to your usual protocol and be sure to obtain the following information to send to Gelflex for all Gelflex Ortho-k orders.

If the patient has previously worn Ortho-k or RGP lenses, ensure they have discontinued wearing the previous lenses for at least **4 weeks** before performing baseline topography.

If the patient has previously worn soft contact lenses, have the patient discontinue wearing their lenses for **1 week** prior to performing baseline topography.

- A. Perform an updated manifest refraction.
- B. High-quality baseline topography maps are essential and should preferably be exported (if you cannot export, please send PDF of Axial, Elevation and Tangential Maps in colour) For instructions on how to export topography please contact Gelflex.
- C. Accurate HVID (Horizontal Visible Iris Diameter)
- D. Perform careful and thorough slit lamp evaluation of cornea, sclera and lids and record your findings
- E. Binocular evaluation
Ensure normal alignment and binocular function at distance and near (Small fixation disparities are not contraindications for Ortho-K, but baseline measurements are critical for post-treatment evaluation)
- F. Patient History
 1. Any history of OK wear including specifications of previous design if possible.
 2. History of any previous contact lens wear
 3. Current Medications
 4. Activities (sports, etc.)
 5. Habitual sleep pattern (hours, waking during the night, read in bed before sleep, etc.)
 6. Inquire about ocular symptoms of dryness, itching, etc.
 7. Inquire about allergies

FITTING GUIDE & LENS CARE

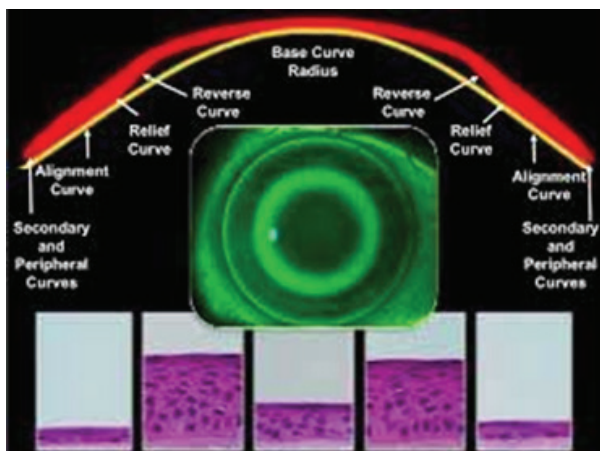
STEP 2 CONTINUED

INITIAL EXAMINATION CONTINUED

Send this information to orders@gelflex.com including the patient's name and your account number for the team to assess.

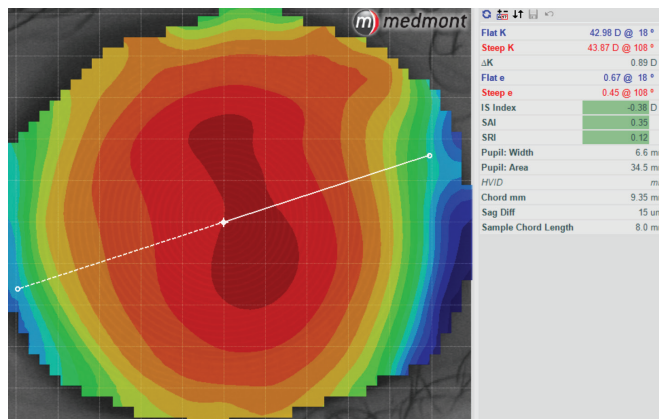
The goal of Ortho-k is to give the patient good unaided acuity throughout the day. While the goal is always to achieve 6/6 vision, in some cases this is not possible. Even if 6/6 vision is not achievable, it is still possible to provide the patient with reasonably good unaided vision and supplemental correction options if necessary. Remember, it is important to have realistic goals before starting this procedure and ensure your patient understands these goals.

ANATOMY OF ORTHO-K LENS



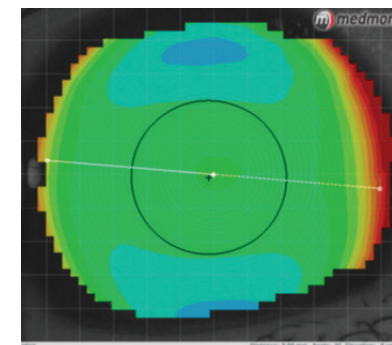
TOPOGRAPHY

Ortho-k, by definition, alters the shape of the cornea. As such, knowing the shape of the cornea at every stage of the process is imperative. Attaining high-quality topography at baseline aids in determining candidacy, initial lens selection and/or lens design. The baseline topography serves as a comparison for every future follow-up visit. The topography maps performed at follow-up visits are the basis for evaluating lens positioning as well as the size, consistency and degree of the treatment.



Baseline corneal axial topography map of the right eye. Note the printout of the Sim Ks, E-Value (eccentricity) in the flat meridian and the steep meridian and sag difference (difference in corneal elevation between the flat and steep meridian at an 8 mm chord diameter) Photo courtesy: M. Lipson

GELFLEX TORIC PERIPHERY design is available for toric corneas. This is determined by reviewing the amount of toricity at the 8mm chord using elevation maps and comparing the difference between the flat and steep axis. The team at Gelflex use this to decide how much toricity to build into the lens.



Baseline elevation map of the same eye as above. Note the blue areas of lower (deeper) elevation superiorly and inferiorly, which is typical of an eye showing with-the-rule astigmatism (Photo courtesy: M. Lipson)

HELPFUL TIPS FOR ATTAINING HIGH-QUALITY TOPOGRAPHY MAPS

1. Ensure the largest possible opening of the eyelids to attain the largest possible area of corneal exposure; this may require help from the patient, parent or another assistant.
2. Use a low-viscosity lubricating drop in the eyes just prior to performing topography.
3. Send us (export) your best two maps per eye to evaluation centration, smoothness and consistency between maps (repeatability). **Instructions on how to export are available upon request.**
4. Evaluate maps to ensure that there are no holes or blank spots (missing data).
5. Evaluate the placido images to ensure that there are smooth ring reflections with no ring overlap (ring jam).
6. Evaluate maps to verify that there is no interference from the eyelids or eyelashes.

FITTING GUIDE & LENS CARE

STEP 2 CONTINUED

AXIAL VS. ELEVATION VS. TANGENTIAL MAPS

Familiarity with the foundations of topography is important to aid in diagnostic evaluation of Ortho-k patients. Each brand of topographer may be slightly different, but the basic maps remain constant:

Axial Map - This is the most commonly used map and provides the most general representation of the corneal contour relative to the optical axis.

Elevation Map - This map is helpful in evaluating the height of the cornea and, specifically, the height difference between different areas of the cornea. Readings are displayed as height relative to a reference sphere calculated by the topographer and described as the "best-fit sphere." This is an important feature in the design of toric alignment and peripheral curves in cases involving astigmatism.

Tangential Map - Sometimes called an "instantaneous map," this map highlights areas of the cornea where sudden changes in corneal shape occur. In Ortho-k, this is particularly important to distinguish the position of the flattened treatment zone that transitions to the steeper area under the reverse curve (the so-called "red ring").

Difference Map - This takes the latest map and compares it to any specified previous map (baseline or other reference map); it displays the change from the reference map to the latest map. It is a very important map that shows exactly what changes have occurred from the baseline or after any lens modifications. It is usually displayed using the axial or tangential maps.

Corneal topography for an ideal Ortho-k candidate will have the following features:

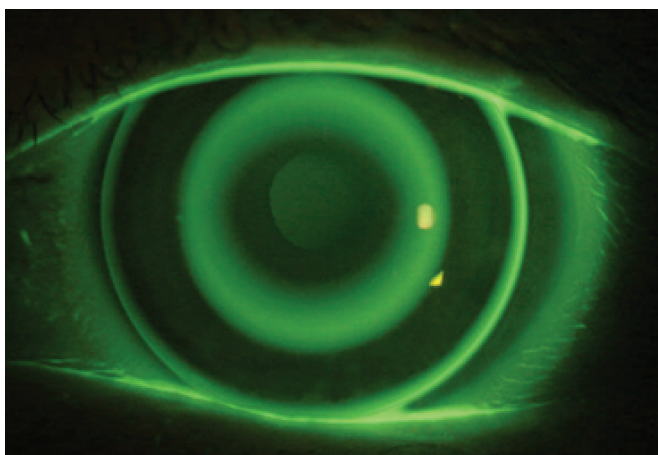
1. A well-centred map with the apex near the geometrical centre of the cornea.
2. Vertical and horizontal symmetry.
3. An average apical radius (41.00 - 45.00 D).
4. A low amount of with-the-rule astigmatism (less than 1.50 D).
5. An average amount of eccentricity (0.25 to 0.80).

STEP 3

LENS DISPENSING & LENS CARE

- A. At the dispensing visit, conduct a slit lamp examination without the lenses prior to application to ensure good ocular health.
- B. Verify you have the correct lenses for your patient.
- C. Apply the lenses and perform O/Rx OVER the lenses. Expected O/Rx is between 0.00 to +0.75, this indicates that the treatment curve is correct. The patient's VA with lenses should be 6/6.
- D. Evaluate fit of lens using NaFl and take pics or videos and keep for your records. Lenses should be well centred and show a small amount of movement. The lens may sit slightly inferior but at this stage it is NOT recommended to make any alterations. However, if any concerns please contact Gelflex.
- E. Compare your NaFl pattern to the image below, is it similar?

If not contact Gelflex Technical Support and provide a picture or video of the NaFl pattern.



STEP 3

Teach application and removal.

Always ensure patient has washed hands thoroughly and correctly before handling lenses.

Teach cleaning, storage and handling techniques.

We recommend the following lens care products and solutions to use with Gelflex Ortho-k lenses:

- Hydrogen peroxide cleaning/disinfection system
- Protein remover
- Preservative-free lubricating eye drops
- Sterile saline solution
- RGP suction lens remover (if applicable)
- Sterile alcohol wipes (to clean surfaces)

A Hydrogen peroxide system is our recommended lens cleaning/disinfection system as it has the highest efficacy of lens sterilisation. Be sure to follow the instructions carefully that are included with the product.

Intensive cleaning with a protein remover is recommended once a month.

Gelflex Ortho-k lenses are colour-coded for right and left. Standard: **gReen lens = right**; **bLue lens = left**.

Other materials and colour options available upon request.

FITTING GUIDE & LENS CARE

STEP 4

FOLLOW UP APPOINTMENTS

Corneal Topography is essential at all visits and your patient **MUST** bring their lenses with them!

Checklist:

- A. Assess unaided visual acuity (monocularly and binocularly)
- B. Assess post-treatment topography
- C. Monitor Corneal Health
- D. Assess Lens Condition

The following are recommended treatment follow up review times but can be altered as you determine appropriate.

- **AM Appointment. after first night's wear**
- 1 Week
- 1 Month
- 3 Months

At the next morning and the 1-week follow-up visits, patients may experience ghosting in vision. This is due to the initial treatment zone on the cornea being smaller than the pupil. As the lens is worn, the central corneal treatment zone will increase in diameter. The majority of ghosting will resolve over time, however if ghosting persists, verify that topography shows a well-centered treatment zone and instruct the patient to continue wear and re-evaluate at next appointment.

The rate of improvement in unaided vision varies with the patient. Factors affecting the rate of change include: degree of baseline myopia, accuracy of fit, hours of wear and individual corneal differences. In general, the full effect of vision improvement with Ortho-k takes 7-10 nights of wear. This will vary from patient to patient.

Once a good fit has been established and the results are within expectations, we recommend you schedule a follow up appointment every **12 months**.

It is critical that the patient brings their lenses to each follow-up appointment. You must ensure patients are following the correct cleaning procedures. Poorly cleaned lenses not only present a risk to the patient's

health they will also negatively impact results. All Ortho-k lenses should be replaced every 12 months as the reverse curve will build up with deposits which are very difficult to remove and may cause discomfort in addition to reducing efficacy.

INSERT *Post-Fitting Topography Assessment Centration*

Centration of an OrthoK lens is one of the most important fitting characteristics necessary to provide optimal visual results. No matter what you observe with regard to lens position in the open eye, the topography tells the story of where the lens is positioned while sleeping. The location of the treatment will indicate whether a change in lens is needed and the type of lens modification required. To evaluate the location of the treatment, it is best to use a tangential difference map.

Difference Maps

As described above, in addition to looking at the post-wear topography, the difference map will provide an excellent display of the exact location and quantity of changes that have occurred.

Patterns

Superior, Inferior, Central Island, Superficial Punctate Keratitis Lenses that are not performing ideally will show various topographic patterns. For example, a superiorly decentered lens will show an inferior arc of steepening beyond the treatment zone (the so-called "smiley face").

TROUBLE SHOOTING

Before making any lens adjustments it is important to make sure the lenses are in the correct eye and the patient is following all lens care, application and removal instructions correctly. If that is the case, then check the following:

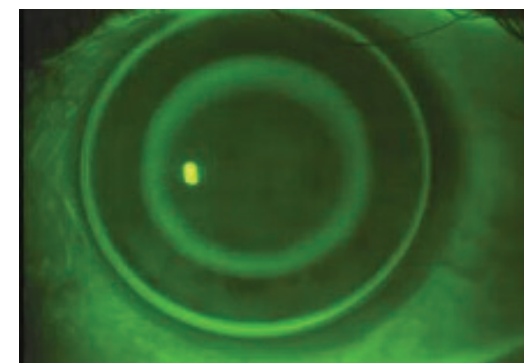
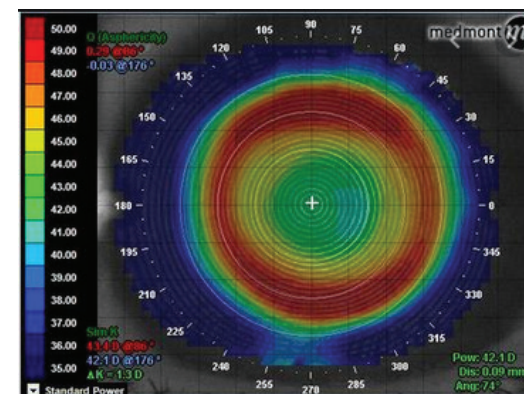
- A. Is the patient getting ~8 hours sleep with lenses in?
- B. Is the patient wearing them every night?
- C. Is the patient using a non-preserved lubricating and Non-Viscous drop at application and removal?
- D. Ensure the patient is not wearing lenses for more than 20 mins prior to sleep.

- E. Ensure the patient is not reading, watching TV, using phone, etc if they wake during the night.
- F. Is the patient following good cleaning and handling procedures as even a fingerprint left on the lens will affect how well the lens performs.

TROUBLE SHOOTING

Post Ortho-k topography - **Good Result** (Bullseye Pattern on Tangential Map)

No need to request any alteration to the lens.

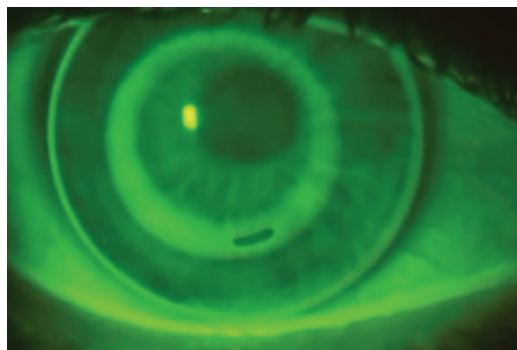
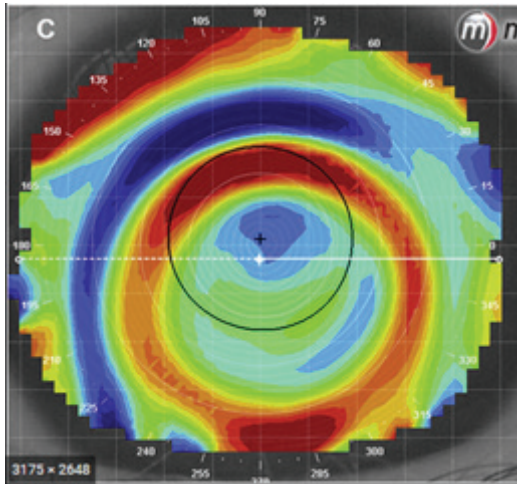


FITTING GUIDE & LENS CARE

STEP 4 CONTINUED

Post Ortho-k Topography - Low Riding Lens
(Frown Face on Tangential Map)

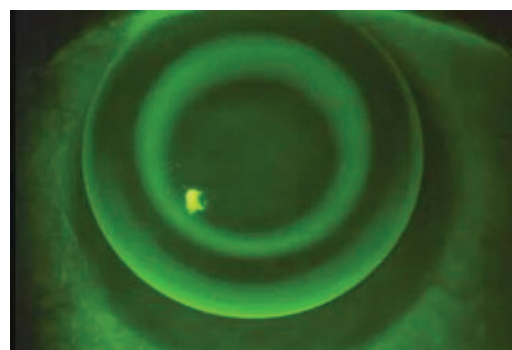
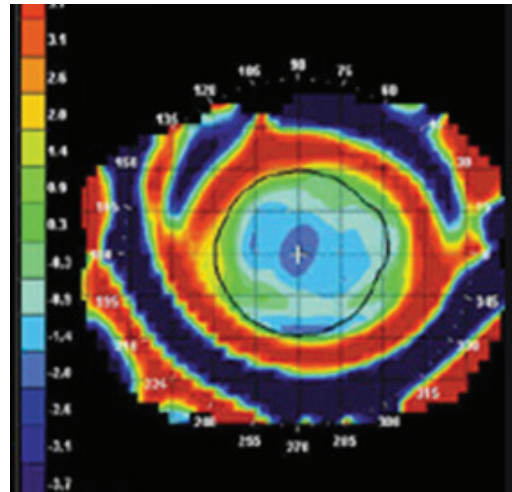
Consider requesting a flatter fit.



Low Riding lens - Steep fit NaFl - Too much sagittal depth

Post Ortho-k Topography - High Riding Lens
(Smile Face on Tangential Map)

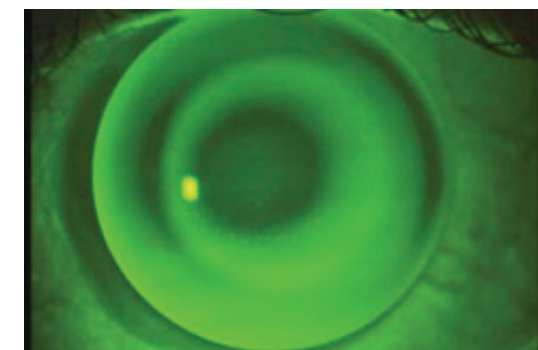
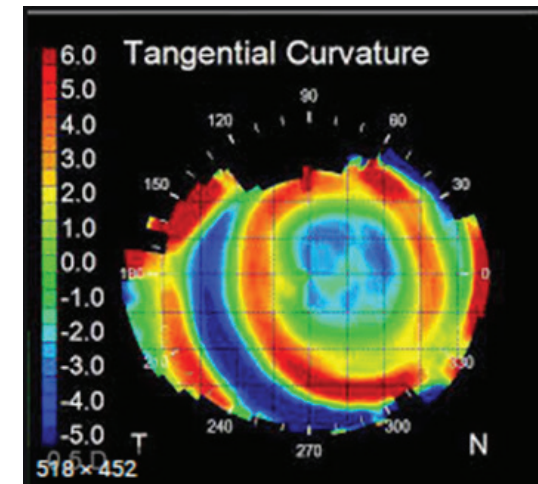
Consider requesting a steeper fit (greater sagittal depth)



High riding lens - Flat fit NaFl - not enough sagittal depth

Post Ortho-k topography - Lateral Riding Lens
(Lateral Crescent on Tangential Map)

Consider requesting a change in diameter.



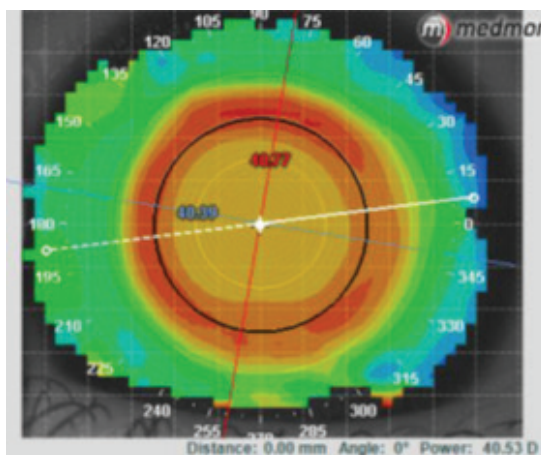
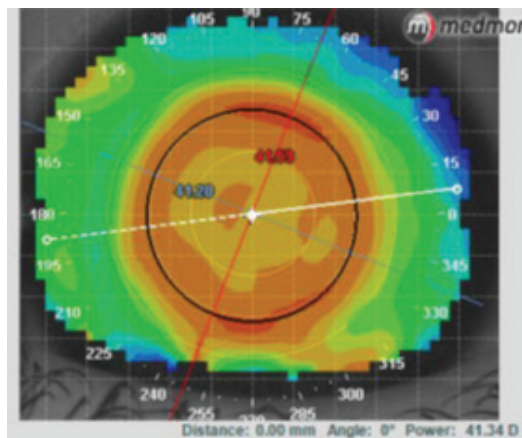
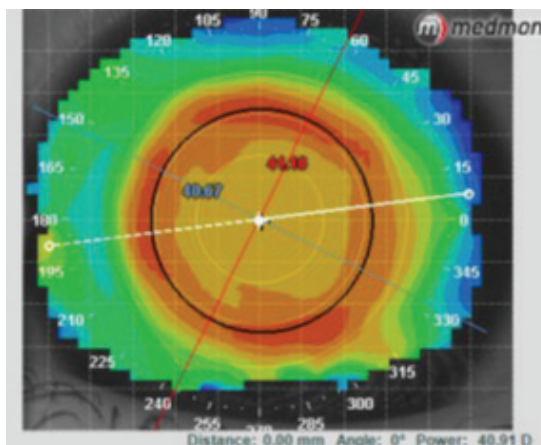
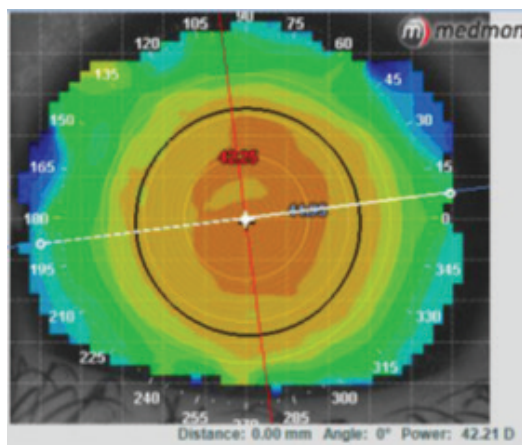
Laterally decentered lens NaFl - Possibly not enough sagittal depth and/or not optimal lens diameter

FITTING GUIDE & LENS CARE

STEP 4 CONTINUED

Trends in topography changes during Ortho-k

Sequential topography at various time points during the process of Ortho-k can indicate ideal treatment vs undesired results. The maps below show the topographical trend for a well-centred case. Note the more defined treatment zone and mid-peripheral ring of steepening from baseline to 1 month.



Tangential maps of a patient over time

Top Left - Baseline

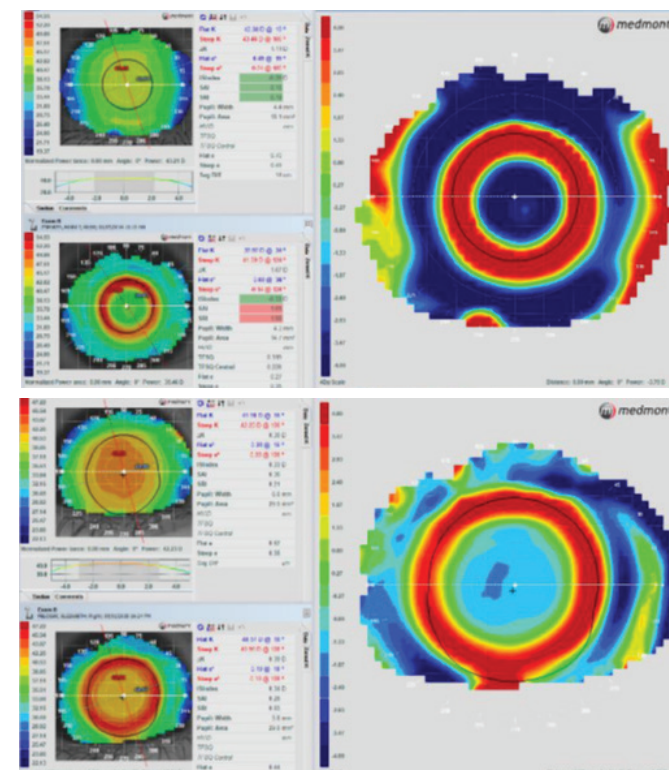
Top Right - 1 Day

Bottom Left - 1 week

Bottom Left - 1 month.

Note the increase in definition of the central treatment zone.

Treatment zone size as viewed with post-treatment topography may vary with lens design, degree of baseline correction and individual patient response. The figure below shows tangential difference maps with distinct differences in diameter of the treatment zone in two patients who are both very successful with excellent unaided acuity.



Top - Tangential difference map with small treatment zone

Bottom - Tangential difference map with large treatment zone

INFORMATION REQUIRED BY GELFLEX FOR CONSULTATION

FOR NEW PATIENTS

- Spectacle refraction
- Corneal topography (Exported or if PDF send axial, tangential and elevation in full colour)
- HVID
- Pupil Diameter
- Age of Patient

FOR EXISTING PATIENTS

- Current issue
- Unaided visual acuity
- Refraction OVER lenses
- Subjective refraction
- Fluorescein Pattern Images
- Post Ortho-k topography - Topography (Exported or if PDF send axial, tangential and elevation in full colour)

Gelflex would like to thank Michael Lipson OD FAAO FSLs for his advice in preparing this document.



Gelflex 
Australian contact lenses

The content of this booklet is correct at the time of distribution, April 2024. F1066-04